

Body surface potential mapping for detection of myocardial infarct sites

Zarychta, P., Smith, F. E., King, S. T., Haigh, A. J., Klinge, A., Zheng, D., Stevens, S., Allen, J., Okelarin, A., Langley, P. & Murray, A.

Published PDF deposited in Coventry University's Repository

Original citation:

Zarychta, P, Smith, FE, King, ST, Haigh, AJ, Klinge, A, Zheng, D, Stevens, S, Allen, J, Okelarin, A, Langley, P & Murray, A 2007, Body surface potential mapping for detection of myocardial infarct sites. in Computers in Cardiology. vol. 34, IEEE, pp. 973-976, Computers in Cardiology Conference, Durham, United States, 30/09/07.

<https://dx.doi.org/10.1109/CIC.2007.4745451>

DOI 10.1109/CIC.2007.4745451

ISSN 0276-6574

Publisher: IEEE

Open access under the terms of the Creative Commons Attribution License.

Copyright © and Moral Rights are retained by the author(s) and/ or other copyright owners. A copy can be downloaded for personal non-commercial research or study, without prior permission or charge. This item cannot be reproduced or quoted extensively from without first obtaining permission in writing from the copyright holder(s). The content must not be changed in any way or sold commercially in any format or medium without the formal permission of the copyright holders.

Body Surface Potential Mapping for Detection of Myocardial Infarct Sites

P Zarychta, FE Smith, ST King, AJ Haigh, A Klinge, D Zheng,
S Stevens, J Allen, A Okelarin, P Langley, A Murray

Newcastle University, Newcastle upon Tyne, UK

Abstract

Using the additional information from multi-lead body surface potential recordings we aimed to study ECG features to predict the extent of infarcted myocardium as part of the 2007 PhysioNet/Computers in Cardiology Challenge.

We studied potential and QT maps through key stages of the ventricular cycle assessing the 2 training and 2 test cases. Clinical assessment of the ECGs was provided by three cardiologists.

QRS axis was abnormal in training case 1. ST was elevated in training case 1 and test case 2. T wave axis was abnormal in training case 2 and test case 1. T wave axis was different to QRS axis in training case 1. Cardiologists agreed that training cases 1 and 2 were anterior and inferior infarctions respectively, while they considered both test cases to be normal variations. The maps, however, showed significant abnormalities in the test cases.

1. Introduction

The 12-lead ECG has long been the standard clinical tool for assessing cardiac disease and can provide general information about the site and extent of myocardial infarction (MI). For example, abnormalities in early depolarisation (Q waves) and early repolarisation (ST segment) are key indicators of chronic and acute MI respectively. The enhanced spatial resolution provided by multiple electrode body surface potential (BSP) systems should allow more detailed information about MI as reported by Mirvis [1]. Our aim was to assess the standard diagnostic ECG features of MI applied to BSP recordings as part of the 2007 PhysioNet/Computers in Cardiology Challenge [2]. The aim of Challenge 2007 is to establish how well one can characterize the location and extent of moderate to large, relatively compact infarcts using electrocardiographic evidence (supplemented by a model of the torso geometry and conductivity), in comparison with a “gold standard” expert analysis of gadolinium-enhanced MRI data.

2. Methods

Data were provided from 4 patients with MI, comprising 352-lead BSP (derived from 120 electrode recordings) and 12-lead ECG. For two of the patients, which constituted the training set, the location and extent of infarct was also provided using a 17 segment classification system [3]. We created maps of body surface potential amplitudes through key stages of the ventricular cycle; depolarisation (QRS), repolarisation (ST segment and T wave) as well as repolarisation interval (QT) measured automatically [4]. Maps were created using map3d [5].

Clinical assessment of 12-lead ECG and 120 lead body surface potential recordings were carried out independently by three cardiologists.

To determine the extent and location of MI for the two patients (test set) for which these were unknown, we compared the maps and clinical assessments for these patients with those from the training set.

3. Results

Figures 1 to 4 show the maps of the QRS, ST, T and QT respectively for the 4 patients. In each figure the front of the torso appears on the left and the rear on the right of the figure and each are scaled independently, potentials in μV , duration in ms. The representative signal at the top of figures 1 to 3 is from training case 1 at node location 258. Training case 2 and test cases 1 and 2 exhibited normal QRS axis, while this was abnormal in training case 1 (figure 1). ST was greater than $200 \mu\text{V}$ in training case 1 and test case 2. All cases had maximum ST in the central chest region, but the area of maximum ST was largest in test case 2 perhaps indicating a greater area of tissue damage relative to the other cases (figure 2). T wave axis was normal in training case 1 and test case 2, but was notably different to QRS axis in all but test case 2 (figure 3). QT maps showed a more complex pattern than the dipolar maps of potentials. Interpretation of the maps was difficult because QT measurements could not be made in some leads due to small amplitude T waves (figure 4).

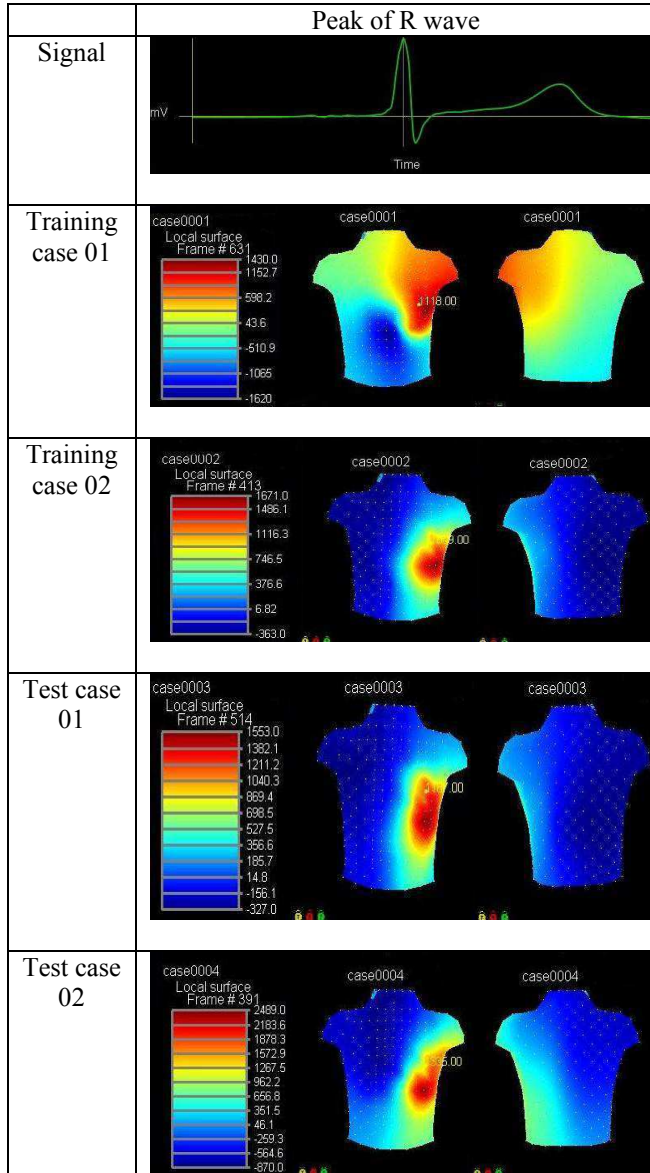


Figure 1. Amplitude maps of 2 training cases and 2 test cases at the peak of the R wave.

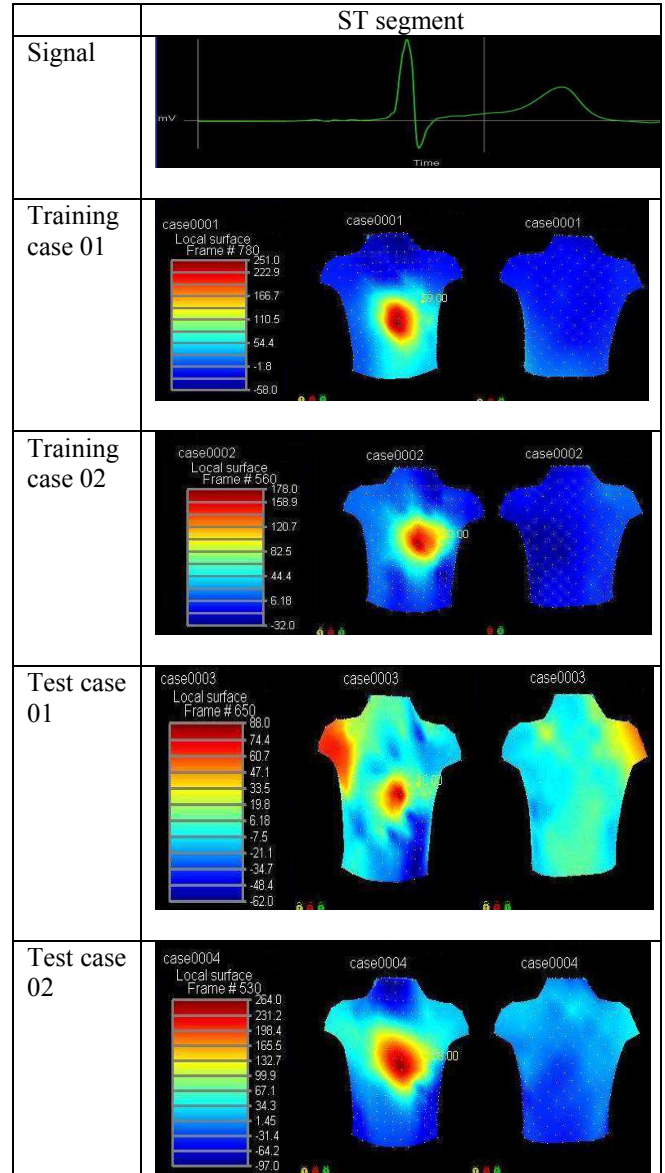


Figure 2. Amplitude maps of 2 training cases and 2 test cases in the ST segment.

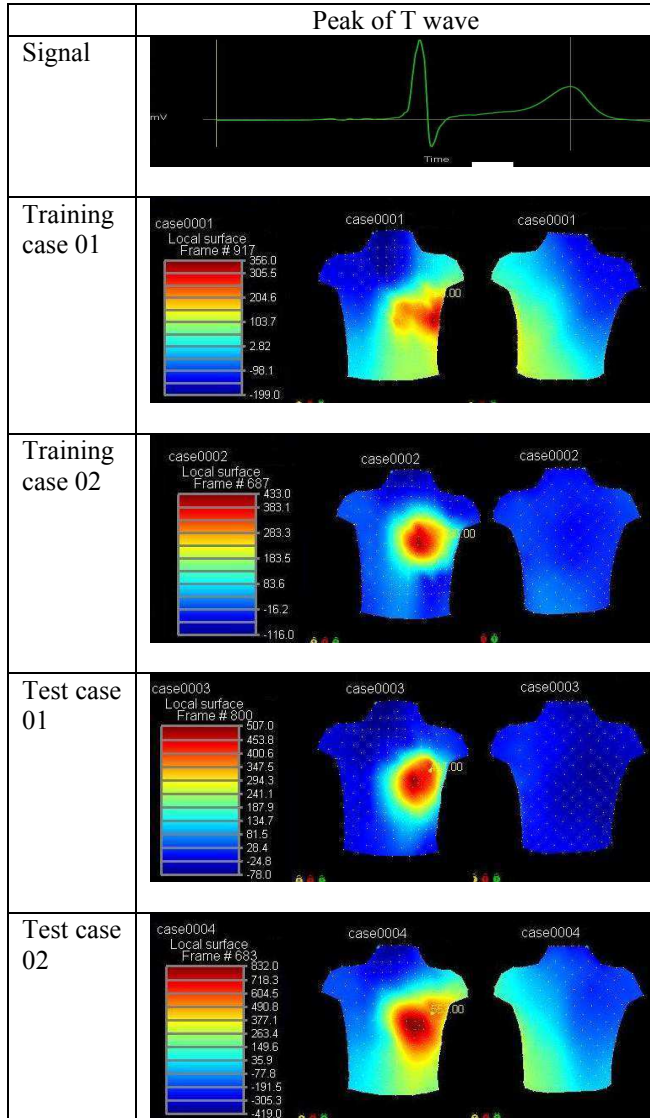


Figure 3. Amplitude maps of 2 training cases and 2 test cases at the peak of the T wave.

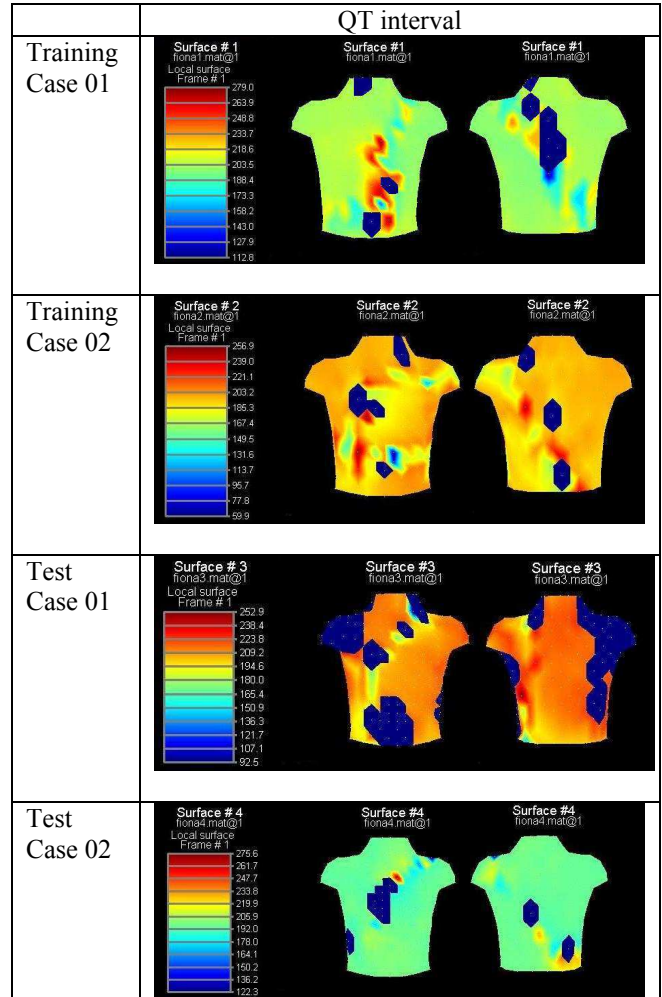


Figure 4. QT interval of 2 training cases and 2 test cases using automated measurements. Blue regions indicate locations where QT could not be measured due to low amplitude T waves.

The clinical interpretations of MI based on analysis of the 12-lead ECG and 120-lead BSPs are reported in table 1. The cardiologists were in broad agreement that training case 1 was an anterior MI, training case 2 inferior MI and the two test cases were normal variations.

Training case 01	Cardiologist 1: anterior septal (V1,V2,V3 localised , ST elevation in V2, recent). Cardiologist 2: anterior (old). Cardiologist 3: septal (ST elevation in V1 & V3).
Training case 02	Cardiologist 1: inferior (Q waves V2, V3 & aVf, MI does not extend into apex, old). Cardiologist 2: inferior (old, incomplete). Cardiologist 3: inferior (Q waves aVf).
Test case 01	Cardiologist 1: normal variation. Cardiologist 2: normal variation. Cardiologist 3: normal variation.
Test case 02	Cardiologist 1: normal variation (U wave abnormality— possibly myopathy, hypertrophy) Cardiologist 2: normal variation. Cardiologist 3: normal variation.

Table 1. Clinical interpretations of cases by cardiologists.

Due to the small training set we were unable to derive an algorithm for location of MI from BSP clinical features, but based on the similarities of maps for training case 2 and test case 1 we concluded that these were similar cases. We were unable to estimate MI location for test case 2. Our results for the test cases and those provided for the training cases are shown in table 2.

Case	Results
Training case 01	extent: 31% segments: 1 2 3 8 9 13 14 15 centroid: 8
Training case 02	extent: 30% segments: 3 4 9 10 centroid: intersection 3, 4, 9, and 10.
Test case 01	extent: 30% segments: 3 4 9 10 centroid: intersection 9.
Test case 02	n/a

Table 2. Final observations from clinical assessment of 12-lead ECG, potential maps and QT interval data.

4. Discussion and conclusions

Based on the limited training set of 2 patients we were unable to derive an algorithm for location of MI site from clinical features of BSP maps. Further analysis based on BSP dynamics or ECG imaging, which provides an estimation of the epicardial potentials from BSPs and detailed anatomical data for each patient (also provided for the Challenge), may provide alternative solutions to this challenge [6].

References

- [1] Mirvis DM. Acute myocardial infarction. In Mirvis DM, eds. Body surface electrocardiographic mapping. Boston: Kluwer Academic; 1988:125-152.
- [2] <http://www.physionet.org/challenge/2007/>
- [3] Cerqueira MD, Weissman NJ, Dilsizian V, Jacobs AK, Kaul S, et al. Standardized myocardial segmentation and nomenclature for tomographic imaging of the heart. *Circulation* 2002;105:539-542.
- [4] Smith FE, Langley P, Trahms L, Steinhoff U, Bourke JP, Murray A. Comparison of automatic repolarization measurement techniques in the normal magnetocardiogram. *PACE* 2003;26:2096-2102.
- [5] <http://www.sci.utah.edu/cibc/software/map3d.html>
- [6] Rudy Y, Burns JE. Noninvasive electrocardiographic imaging. *A.N.E.* 1999;4:340-359.

Address for correspondence

P Langley
Medical Physics Department
Freeman Hospital
Newcastle upon Tyne
philip.langley@ncl.ac.uk