

Diagnostic Value of Chest CT scan for COVID-19 Suspected Cases and Its Compatibility with RT-PCR Method: A Survey from Jiroft, Iran

Razzaghi, A., Sardu, E. G., Kargar, S., Barfar, E., Yusefi, A. R., Hoveidaei, A., Clark, C. C. T. & Daneshi, S.

Published PDF deposited in Coventry University's Repository

Original citation:

Razzaghi, A, Sardu, EG, Kargar, S, Barfar, E, Yusefi, AR, Hoveidaei, A, Clark, CCT & Daneshi, S 2022, 'Diagnostic Value of Chest CT scan for COVID-19 Suspected Cases and Its Compatibility with RT-PCR Method: A Survey from Jiroft, Iran', *Open Public Health Journal*, vol. 15, no. 1, e187494452206201.

<https://doi.org/10.2174/18749445-v15-e2206201>

DOI 10.2174/18749445-v15-e2206201

ISSN 1874-9445

Publisher: Bentham Open

© 2022 Razzaghi et al.

Open-Access License: This is an open access article distributed under the terms of the Creative Commons Attribution 4.0 International Public License (CC-BY 4.0), a copy of which is available at:

<https://creativecommons.org/licenses/by/4.0/legalcode>

This license permits unrestricted use, distribution, and reproduction in any medium, provided the original author and source are credited.



The Open Public Health Journal

Content list available at: <https://openpublichealthjournal.com>



RESEARCH ARTICLE

Diagnostic Value of Chest CT scan for COVID-19 Suspected Cases and Its Compatibility with RT-PCR Method: A Survey from Jiroft, Iran

Alireza Razzaghi¹, Ehsan Goroei Sardu², Shiva Kargar³, Eshagh Barfar⁴, Ali Reza Yusefi⁵, Armin Hoveidaei⁶, Cain C. T. Clark⁷ and Salman Daneshi^{8,*}

¹Road Traffic Injury Research Center, Tabriz University of Medical Sciences, Tabriz, Iran

²Clinical Research Development Unit of Imam Khomeini Hospital, Jiroft University of Medical Sciences, Jiroft, Iran

³MSc Student of Epidemiology, School of Health, Zahedan University of Medical Sciences, Zahedan, Iran

⁴Health Promotion Research Center, Zahedan University of Medical Science, Zahedan, Iran

⁵Assistant Professor of Health Services Management, Department of Public Health, School of Health, Jiroft University of Medical Science, Jiroft, Iran

⁶Student Research Committee, School of Allied Medical Sciences, Shahid Beheshti University of Medical Sciences, Tehran, Iran

⁷Centre for Intelligent Healthcare, Coventry University, Coventry, CV1 5FB, U.K.

⁸Department of Public Health, School of Health, Jiroft University of Medical Sciences, Jiroft, Iran

Abstract:

Introduction:

Accurate diagnosis of the COVID-19 disease is important. Currently, chest computed tomography (CT) and reverse polymerase chain reaction (RT-PCR) are being used for the diagnosis of the COVID-19 disease. This study was performed to evaluate the Chest computed tomography (CT) diagnostic value in comparison with the RT - PCR method among COVID-19 patients.

Methods:

This cross-sectional study was performed on suspected cases of COVID-19 in Imam Khomeini Hospital, Jiroft, Iran. Studied patients were evaluated *via* both a chest CT scan and nasopharyngeal swab for SARS-CoV-2 detection. Data was collected using a self-administered checklist, including demographic information, medical history, and symptoms of COVID-19, chest CT scan, and RT-PCR findings. Data were analyzed using SPSS-V21.

Results:

One thousand and ninety (1090) cases participated in the study; the mean age of the cases of COVID-19 was 48.20± 7.31 years old. The results of the RT-PCR test were 410 (37.6%) positive and 680 (62.4%) negative cases. According to the results of RT-PCR, which is the gold standard method, the sensitivity, specificity, accuracy, positive predictive value, and negative predictive values of chest CT were 98.5%. (99.4-96.8 CI: 95%), 55.7% (59.5 – 51.9 CI: 95%), 71.5% (74.4 -69.0 CI: 95%), 57.3% (60.9 – 53.5 CI: 95%), and 98.4% (99.4% - 99.6 CI: 95%), respectively.

Discussion:

The results of the present study showed that a chest CT scan is highly sensitive for the diagnosis of the COVID-19 disease. Therefore, it can be used as a suitable method for screening and early detection, which requires knowledge of its common radiologic patterns. However, the results showed that the use of this method has low specificity, so it cannot be used for definitive diagnosis and should be used as a complementary method concomitant to the RT - PCR test.

Keywords: Chest CT scan, COVID-19, RT-PCR, Patients, SARS-CoV-2, MERS.

Article History

Received: August 22, 2021

Revised: January 27, 2022

Accepted: March 3, 2022

1. INTRODUCTION

In late December 2019, the novel coronavirus (SARS-CoV-2 or COVID-19) triggered the worldwide spread of

uncommon pneumonia emanating from Wuhan, China. Studies have shown that the origin of the disease was likely in the market of seafood, poultry, and live animals in this city [1, 2].

The new coronavirus (SARS-CoV-2) belongs to the beta-coronavirus classification and is the third coronavirus outbreak, after the SARS and MERS viruses in the two previous decades.

* Address correspondence to this author at the Department of Public Health, School of Health, Jiroft University of Medical Sciences, Jiroft, Iran; Tel: 03443310916; E-mail: salmandaneshi008@gmail.com

Phylogenetic analysis shows that the new coronavirus is closely related to the SARS bat coronavirus. Regarding these findings, it is plausible that the new virus experienced zoonotic transmission in the Wuhan market [3].

There is a wide variety of clinical manifestations of COVID-19, including asymptomatic cases, upper respiratory tract infection, severe viral pneumonia, respiratory failure, and even death; however, hospital admission is needed for only a few cases [4]. Fever, cough, shortness of breath, fatigue, diarrhea, nausea, and sore throat represent the most common symptoms [5]. Imaging findings also include patchy bilateral shadow, interstitial abnormalities, and focal ground-glass opacity in chest computed tomography (CT) scans. Moreover, lymphopenia, neutropenia, and thrombocytopenia have also been reported among the laboratory criteria in COVID-19 patients, and lymphopenia was shown to be remarkable in severely ill cases [6].

As there is no definitive treatment or optimal vaccination method for this disease, early diagnosis of the patients and their isolation is essential to reduce the spread of the disease in society [7]. One of the rapid diagnostic methods for the disease is chest CT scan; however, using this method is controversial and may lead to a confusing interpretation in abnormal cases [8 - 10]. Reverse polymerase chain reaction, or RT-PCR, as a cellular-molecular diagnostic test is another diagnostic method for this purpose, it has sufficient sensitivity and specificity, so it is the most common method. On the other hand, the use of the CT scan method requires less time than the cellular molecular method [11, 12]. Indeed, detection of the cases in the early stages of the disease is an effective way to reduce its prevalence and mortality. This study was performed to evaluate and compare chest CT scan and RT-PCR for the diagnosis of suspected cases of COVID-19.

2. METHODS

This cross-sectional study was performed from April to June 2020 to evaluate the diagnostic value of chest CT scan and RT-PCR nasopharyngeal swab specimens among COVID-19 suspected cases in the emergency department of Imam Khomeini Hospital in Jiroft, Iran.

The study sample included COVID-19 suspected patients who were tested for the diagnosis of COVID-19 via RT-PCR through a nasopharyngeal swab specimen and a chest CT scan, with an interval of less than a week. Individuals who had a CT scan and nasopharyngeal swab sample interval of more than seven days were excluded from the study. Data were collected using a self-administered checklist, including demographic information, history of common symptoms of COVID-19 such as (fever, cough, etc.), chest CT and RT-PCR test results that were obtained from the picture archive and communication systems (PACS), Radiology Information System (RIS) and Hospital Information System (HIS). After completing the checklist, the collected data were entered into SPSS-v21 (SPSS Inc., Chicago, IL, USA) software and analyzed using descriptive statistics. Chi-square, Fisher, and univariate logistic regression tests were also used to investigate the relationship between qualitative variables and the results of RT-PCR and chest CT scan tests. A value of $p < .05$ was considered to be significant. In addition, sensitivity, specificity, positive predictive value, negative predictive value, and accuracy indices of chest CT were calculated via the following formulas:

1. Accuracy = $\frac{TP+TN}{[TP+TN+FP+FN]}$
2. Sensitivity = $\frac{TP}{TP+FN}$
3. Specificity = $\frac{TN}{TN+FP}$
4. positive predictive value = $\frac{Tp}{Tp+FP}$
5. negative predictive value = $\frac{TN}{TN+FN}$

TP: The total number of patients with acute and moderate conditions, identified correctly by the system.

TN: The total number of patients with a mild condition, identified correctly by the system.

FP: The total number of patients with acute and moderate conditions, not identified correctly by the system.

FN: The total number of patients with a mild condition, not identified correctly by the system.

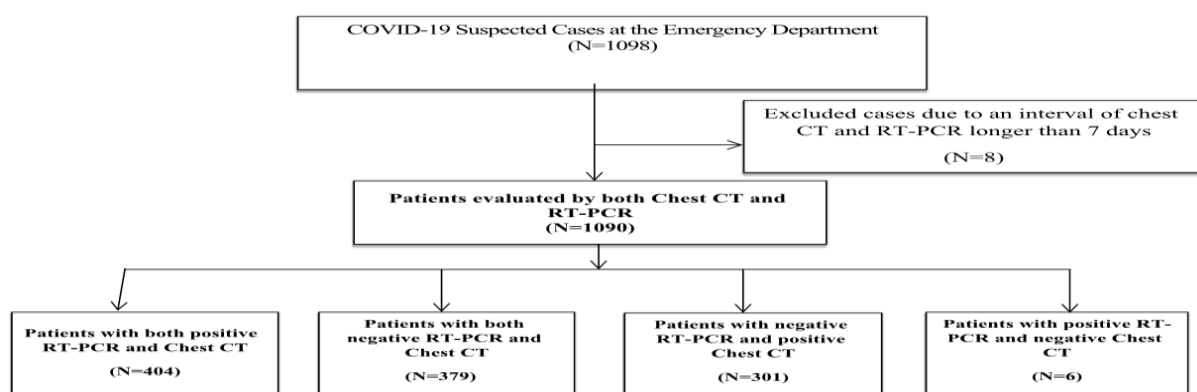


Fig. (1). Diagram of the study process.

Table 1. Frequency of the patients’ distribution in the study based on demographic characteristics (N = 1090).

Frequency (Percent)	Variables
31/7 ± 20/48	age (mean standard ± deviation)
	Gender
512 [47]	Male
578 [53]	Female
	Chest CT findings
517 [47.4]	Ground glass opacity (GGO)
129 [11.4]	Progressive release
67 [6.1]	Consolidation
	Background disease
119 [10.9]	Hypertension
91 [8.3]	Chronic obstructive pulmonary disease
78 [7.1]	Diabetes Mellitus
102 [9.3]	Chronic heart disease (CHD)
25 [2.2]	Chronic kidney disease (CKD)
	Symptoms associated with COVID-19
896 [82.2]	Fever
764 [70]	Cough
391 [35.8]	Dyspnea
119 [10.9]	Chest discomfort
61 [5.6]	Hemoptysis
143 [13.1]	Sore throat

3. RESULTS

From 1098 patients, suspected cases of COVID-19 were referred to the emergency department. Patients were excluded because of the time interval of more than 7 days between RT-PCR and chest CT scan. Therefore, 1090 patients were included in the study, of which 578 (53%) were female and 512 (47%) were male, and the mean age was 48.20 ± 7.31 years. As shown in Table 1, 82.2 % of patients had symptoms of fever (38 degrees), 70% cough, and 35.8% dyspnea at the emergency department of the hospital. The most common observed pattern in chest CT-Scan of these patients was Grand Glass Opacity (GGO), with a frequency of 47.4%. Moreover, the most common patterns were progressive diffusion patterns (11.4) and consolidation (6.1) (Table 1).

Table 2 shows the RT-PCR and chest CT scan function in the diagnosis of COVID-19. Out of a total of 1090 patients, 410 (37.6%) were positive for RT-PCR and 680 (62.4%) were negative. Out of 410 patients who were positive for RT-PCR, 404 were positive for chest CT evaluation. Also, out of 680

people who were negative for RT-PCR, 379 people were negative for chest CT scan. Overall, 705 patients (64.6%) were identified as having a high risk of COVID-19 based on CT-Scan findings. Based on the results of RT-PCR as gold standard, sensitivity, specificity, and accuracy of chest CT in COVID-19 were estimated at 98.5% (99.4-96.8: 95% CI), 55.7% (51.9 – 59.5: 95% CI), was 71.5% (74.4- 69.0: 95% CI), respectively. Also, the positive predictive value of chest CT was 57.3% (60.5 - 53.5: 95% CI) and the negative predictive value of chest CT was 98.4% (95.4% CI: 99.6-6.4.4).

Table 3 presents the relationship between the chest CT scan and RT-PCR results and qualitative variables. There was a statistically significant relationship between RT-PCR and chest CT scan findings in different groups based on previous medical history, CT scan findings, cough, sore throat, bloody sputum, chest discomfort, and dyspnea (P <0.05). However, there was no statistically significant relationship between RT-PCR and chest CT results according to sex (P = 0.35, P = 0.48) (Table 3).

Table 2. The RT-PCR and Chest CT scan function in the diagnosis of COVID-19.

		Frequency (Percentage)	Sensitivity CI 95%	Specificity CI 95%	PPV CI 95%	NPV CI 95%	Accuracy CI 95%
RT-PCR [Gold standard]	Positive	410 [37.6%]	-	-	-	-	-
	Negative	680 [62.4%]					
Chest CT scan	Positive	705 [64.6%]	98.5	55.7	57.3	98.4	71.8
	Negative	385 [35.1%]	96.8 – 99.4	[51.9 – 59.5]	[53.5 -60.9]	[96.6 -94.4]	[69.0 – 74.4]

Table 3. The relationship between the chest Chest CT and RT-PCR results based qualitative variables.

P-value	PCR Results		P-value	CT-Scan results		Subgroup	Variable
	Negative	Positive		Negative	Positive		
0.35	316	196	0.43	179	333	Male	Gender
	364	214		206	372	Female	
<0.05	680	410		385	705	Total	
	675	0	<0.05	374	301	Negative	Past Medical History
	4	115		8	111	Hypertension	
	0	91		0	91	Chronic obstructive pulmonary disease	
	1	77		3	75	Diabetes Mellitus	
	0	102		0	102	Chronic heart disease [CHD]	
	0	25		0	25	Chronic kidney disease [CKD]	
<0.05	680	410		385	705	Total	
	40	164	<0.05	40	164	No	Fever
	640	246		640	246	Yes	
<0.05	680	410		385	705	Total	
	371	6	<0.05			Negative	CT findings
	190	327				Ground glass opacity [GGO]	
	77	56				Progressive release	
	42	25				Consolidation	
<0.05	680	410				Total	cough
	67	259	<0.05	42	284	No	
	613	151		343	421	Yes	
<0.05	680	410		385	705	Total	Sore throat
	656	291	<0.05	364	583	No	
	24	119		21	122	Yes	
<0.05	680	410		385	705	Total	Hemoptysis
	649	380	<0.05	373	656	Yes	
<0.05	31	30		12	49	No	
<0.05	680	410		385	705	Total	Chest discomfort
	363	971	<0.05	356	615	Yes	
	72	47		29	90	No	
<0.05	680	410		385	705	Total	dyspnea
	536	163	<0.05	307	392	Yes	
	144	247		78	313	No	
	680	410		385	705	Total	

4. DISCUSSION

This study sought to evaluate the diagnostic value of chest CT and RT-PCR in suspected COVID-19 patients referred to the emergency room of Imam Khomeini Hospital, Jiroft in 2020. Imaging represents a good diagnostic tool for COVID-19 suspected cases, as it indicates the severity and progression of COVID-19 disease. Compared to RT-PCR, chest CT scan is a more reliable, easier, and faster tool to identify and evaluate cases of COVID-19 [13 - 16]. Therefore, being aware of the imaging manifestations of the emerging COVID-19 disease is essential for all radiologists and radiology departments around the world. These manifestations include the presence of GGO, Crazy-Paving Pattern, Consolidation, number of lobes involved in grand glass turbidity, the degree of involvement of each lobe, the presence of nodules, and the presence of pleural effusion [17 - 19].

Preliminary results have shown that a low-dose CT scan, which is a widely available and relatively inexpensive imaging

technique in Iran, is effective for the diagnosis of COVID-19 in suspected patients [10]. In addition, the current pattern of chest CT scan reports can be used to classify and predict which patients should be treated and discharged in an outpatient setting, which patients need further evaluation and monitoring, and even identifying need for ICU admission if necessary [20].

The results of the present study showed that the sensitivity of chest CT scan was 98.5%, which is consistent with the results of the studies by Fang *et al.* [21], Lung *et al.* [22], Ai *et al.* [23], Caruso *et al.* [24], and Kim *et al.* [25], and confirms the high sensitivity of this method in the diagnosis of COVID -19. Due to the high sensitivity of CT-Scan, it is therefore suitable for screening the suspected COVID-19 cases.

This study showed that the specificity of CT scan was 55.7%. It has been reported as 53%, 26%, 26%, 97%, 97%, and 37% by Hemito *et al.* [26], Cheng *et al.* [27], Ai *et al.* [23], Caruso *et al.* [24], and Kim *et al.* [25] studies, respectively, which is concordant with the results of the present study and

confirms that chest CT scan may not represent a suitable method for definite diagnosis due to the low specificity.

The findings of the present study demonstrated that the most common pattern observed in the CT scan of COVID-19 patients was Ground-glass opacity (GGO), with a frequency of 74.6%, which was consistent with the results of Caruso *et al.* [24] and Lung *et al.* [22].

Fang *et al.* [2020] conducted a descriptive-analytic cross-sectional study in China to evaluate changes in CT scan images of COVID-19 patients from the early stages of the disease to recovery and discharge from the hospital. The results of their study showed that, in the early stages (0-4 days after the first signs of the disease), GGO was the most obvious radiological sign on CT images, seen as subpleural in the lower lobes unilaterally or bilaterally. In four patients, CT scan was normal at this stage, but abnormal findings were also seen on their CT scan. Five to eight days after the onset of the first symptoms, the progressive stage of the disease was seen on CT scan images. At this stage, the infection intensified rapidly and spread bilaterally to the lung lobes. In the advanced stage, GGOs were released with a rapid release pattern in the lung lobes. In patients with COVID-19 who were in the recovery period [patients without respiratory distress syndrome], lung abnormalities on chest CT scans showed their highest severity on approximately the tenth day of the disease. Further, lung involvement increased rapidly within two weeks of the onset of COVID-19 disease, where the highest peak of lung involvement occurred on days 9 to 13 of the disease. At this stage, dense areas were seen at the involved parts of the lungs and large generalized dense GGOs that also produced parenchymal lesions. From the fourteenth day onwards, the GGOs were dissected, and the lesions of the lung infection gradually disappeared [21].

Therefore, due to the high infectivity of COVID-19 and the lack of specific proven treatment and fully effective vaccines against it, early diagnosis of this disease is so important. Also, due to the limited number of nucleic acid test kits, such as RT-PCR and the possibility of false-negative RT-PCR results, chest CT imaging as a non-invasive imaging technique can be useful for screening for early detection of COVID-19 suspected cases [18]. However, it requires knowing the common radiological findings in these patients. When a radiologist observes common chest imaging findings from this new strain of coronavirus, they can detect the cases based on epidemiological and demographic characteristics. The limitations of this study included the following; the short duration of the study, limited clinical and laboratory data due to the urgency of the situation, and limitations related to the lack of randomized clinical trial (RCT) research. Further surveys should be conducted more comprehensively to elucidate our findings.

CONCLUSION

Overall, the results of the present study showed that the use of chest CT scan to diagnose COVID-19 disease is very sensitive, and thus may be used as a method for screening and early diagnosis, which requires knowledge of common radiological patterns of the disease. However, the use of this

method has low specificity, so it cannot be used for definitive diagnosis. Accordingly, complementary methods such as PCR testing should be used in addition.

LIST OF ABBREVIATIONS

CT	=	Computed Tomography
RT-PCR	=	Polymerase Chain Reaction
RIS	=	Radiology Information System
HIS	=	Hospital Information System

ETHICS APPROVAL AND CONSENT TO PARTICIPATE

This study was approved by the Ethics Committee of University of Medical Sciences, Jiroft, Iran. Ethics code: IR.JMU.REC.1399.039.

HUMAN AND ANIMAL RIGHTS

No animals were used that are the basis of this study. All the human procedure were performed in accordance with the helsinki declaration.

CONSENT FOR PUBLICATION

Informed consent was obtained from the participants.

STANDARDS OF REPORTING

STROBE guidelines were followed.

AVAILABILITY OF DATA AND MATERIALS

Not applicable.

FUNDING

None.

CONFLICT OF INTEREST

The authors declare no conflicts of interest.

ACKNOWLEDGEMENTS

Declared none.

REFERENCES

- [1] Lai CC, Shih TP, Ko WC, Tang HJ, Hsueh PR. Severe acute respiratory syndrome coronavirus 2 (SARS-CoV-2) and coronavirus disease-2019 (COVID-19): The epidemic and the challenges. *Int J Antimicrob Agents* 2020; 55(3): 105924. [http://dx.doi.org/10.1016/j.ijantimicag.2020.105924] [PMID: 32081636]
- [2] Yusefi AR, Daneshi S, Davarani ER, Nikmanesh P, Mehralian G, Bastani P. Resilience level and its relationship with hypochondriasis in nurses working in COVID-19 reference hospitals. *BMC Nurs* 2021; 20(1): 219. [http://dx.doi.org/10.1186/s12912-021-00730-z] [PMID: 34727947]
- [3] Pal M, Berhanu G, Desalegn C, Kandi V. Severe acute respiratory syndrome coronavirus-2 (SARS-CoV-2): an update. *Cureus* 2020; 12(3): e7423. [http://dx.doi.org/10.7759/cureus.7423] [PMID: 32337143]
- [4] Rezabeigi-Davarani E, Bokaie S, Mashayekhi V, *et al.* Epidemiological and Clinical Characteristics of COVID-19 Patients Studied by Jiroft University of Medical Sciences: Southeast of Iran. *J Adv Med and Biomed Res* 2021; 29(136): 302-8. [http://dx.doi.org/10.30699/jams.29.136.302]
- [5] Bahonar A. Evaluation of the first symptom and evaluation of

- olfactory and taste disorders during the course of the disease and its related factors in patients with COVID-19. *J Milit Health Promo* 2021; 2(1): 286-93. [<http://military-health.ir/article-1-62-en.html>].
- [6] Liu T, Zhang J, Yang Y, *et al.* The potential role of IL-6 in monitoring coronavirus disease SSRN 2019; 3548761. [<http://dx.doi.org/10.2139/ssrn.3548761>]
- [7] Yang Y, Yang M, Shen C, *et al.* Laboratory diagnosis and monitoring the viral shedding of 2019-nCoV infections. *MedRxiv* 2020. [<http://dx.doi.org/10.1016/j.xinn.2020.100061>]
- [8] Huang C, Wang Y, Li X, *et al.* Clinical features of patients infected with 2019 novel coronavirus in Wuhan, China. *Lancet* 2020; 395(10223): 497-506. [[http://dx.doi.org/10.1016/S0140-6736\(20\)30183-5](http://dx.doi.org/10.1016/S0140-6736(20)30183-5)] [PMID: 31986264]
- [9] Lei J, Li J, Li X, Qi X. CT imaging of the 2019 novel coronavirus [2019-nCoV] pneumonia. *Radiology* 2020; 295(1): 18. [<http://dx.doi.org/10.1148/radiol.2020200236>] [PMID: 32003646]
- [10] Chung M, Bernheim A, Mei X, *et al.* CT imaging features of 2019 novel coronavirus. *Radiology* 2020; 295(1): 202-7. [<http://dx.doi.org/10.1148/radiol.2020200230>] [PMID: 32017661]
- [11] Corman VM, Landt O, Kaiser M, *et al.* Detection of 2019 novel coronavirus (2019-nCoV) by real-time RT-PCR. *Euro Surveill* 2020; 25(3): 2000045. [<http://dx.doi.org/10.2807/1560-7917.ES.2020.25.3.2000045>] [PMID: 31992387]
- [12] Reusken CBEM, Broberg EK, Haagmans B, *et al.* Laboratory readiness and response for novel coronavirus (2019-nCoV) in expert laboratories in 30 EU/EEA countries, January 2020. *Euro Surveill* 2020; 25(6): 2000082. [<http://dx.doi.org/10.2807/1560-7917.ES.2020.25.6.2000082>] [PMID: 32046815]
- [13] Zhu N, Zhang D, Wang W, *et al.* A novel coronavirus from patients with pneumonia in China, 2019. *N Engl J Med* 2020; 382(8): 727-33. [<http://dx.doi.org/10.1056/NEJMoa2001017>] [PMID: 31978945]
- [14] Wang C, Horby PW, Hayden FG, Gao GF. A novel coronavirus outbreak of global health concern. *Lancet* 2020; 395(10223): 470-3. [[http://dx.doi.org/10.1016/S0140-6736\(20\)30185-9](http://dx.doi.org/10.1016/S0140-6736(20)30185-9)] [PMID: 31986257]
- [15] Bernheim A, Mei X, Huang M, *et al.* Chest CT findings in coronavirus disease-19 [COVID-19]: relationship to duration of infection. *Radiology* 2020; 295(3): 200463. [<http://dx.doi.org/10.1148/radiol.2020200463>] [PMID: 32077789]
- [16] Xie Y, Wang X, Yang P, Zhang S. COVID-19 complicated by acute pulmonary embolism. *Radiol Cardiothorac Imaging* 2020; 2(2): e200067. [<http://dx.doi.org/10.1148/ryct.2020200067>] [PMID: 33778561]
- [17] Wong J, Goh QY, Tan Z, Lie SA, Tay YC, Ng SY, *et al.* Preparing for a COVID-19 pandemic: A review of operating room outbreak response measures in a large tertiary hospital in Singapore. *Canadian J Anesth* 2020; 67(6): 732-45. [<http://dx.doi.org/10.1007/s12630-020-01620-9>]
- [18] Lauer SA, Grantz KH, Bi Q, *et al.* The incubation period of coronavirus disease 2019 [COVID-19] from publicly reported confirmed cases: estimation and application. *Ann Intern Med* 2020; 172(9): 577-82. [<http://dx.doi.org/10.7326/M20-0504>] [PMID: 32150748]
- [19] Haifeng L, ZHANG D, Yi Y, Bin L, Long Y, Ming Z. Analysis of early chest high resolution CT images of novel coronavirus pneumonia. *Chinese J Radiol* 2020; E007-E. <https://pesquisa.bvsalud.org/portal/resource/pt/wpr-811617>
- [20] Mahdavi A, Khalili N, Davarpanah AH, *et al.* Radiologic management of COVID-19: preliminary experience of the Iranian Society of Radiology COVID-19 Consultant Group. *Iran J Radiol* 2020; 17(2): 17. [<http://dx.doi.org/10.5812/iranradiol.102324>]
- [21] Fang Y, Zhang H, Xie J, *et al.* Sensitivity of Chest CT for COVID-19: Comparison to RT-PCR. *Radiology* 2020; 296(2): E115-7. [<http://dx.doi.org/10.1148/radiol.2020200432>] [PMID: 32073353]
- [22] Long C, Xu H, Shen Q, *et al.* Diagnosis of the Coronavirus disease (COVID-19): rRT-PCR or CT? *Eur J Radiol* 2020; 126: 108961. [<http://dx.doi.org/10.1016/j.ejrad.2020.108961>] [PMID: 32229322]
- [23] Ai T, Yang Z, Hou H, *et al.* Correlation of chest CT and RT-PCR testing for coronavirus disease 2019 [COVID-19] in China: a report of 1014 cases. *Radiology* 2020; 296(2): E32-40. [<http://dx.doi.org/10.1148/radiol.2020200642>] [PMID: 32101510]
- [24] Caruso D, Zerunian M, Polici M, *et al.* Chest CT Features of COVID-19 in Rome, Italy. *Radiology* 2020; 296(2): E79-85. [<http://dx.doi.org/10.1148/radiol.2020201237>] [PMID: 32243238]
- [25] Kim H, Hong H, Yoon SH. Diagnostic performance of CT and reverse transcriptase polymerase chain reaction for coronavirus disease 2019: a meta-analysis. *Radiology* 2020; 296(3): E145-55. [<http://dx.doi.org/10.1148/radiol.2020201343>] [PMID: 32301646]
- [26] Himoto Y, Sakata A, Kirita M, *et al.* Diagnostic performance of chest CT to differentiate COVID-19 pneumonia in non-high-epidemic area in Japan. *Jpn J Radiol* 2020; 38(5): 400-6. [<http://dx.doi.org/10.1007/s11604-020-00958-w>] [PMID: 32232648]
- [27] Cheng Z, Lu Y, Cao Q, *et al.* Clinical features and chest CT manifestations of coronavirus disease 2019 [COVID-19] in a single-center study in Shanghai, China. *AJR Am J Roentgenol* 2020; 215(1): 121-6. [<http://dx.doi.org/10.2214/AJR.20.22959>] [PMID: 32174128]